



CLINICAL IMAGES

Adrenal rest tumours in congenital adrenal hyperplasia

Ekkehard W Zöllner, Richard Pitcher

Classic congenital adrenal hyperplasia (CAH) due to 21-hydroxylase deficiency is rare, occurring approximately once in every 15 000 live births.¹ At birth it is often suspected in girls because of ambiguous genitalia, whereas boys have normal genitalia. The salt-losing type of CAH presents with adrenal crisis a few weeks after birth, while the simple type manifests virilisation and rapid growth years later. The diagnosis is confirmed by an elevated plasma 17-hydroxyprogesterone (17-OHP) level. Additional features in the salt-losing variety are hyponatraemia, hyperkalaemia, metabolic acidosis and an elevated plasma renin level. The gluco- and mineralocorticoid insufficiency is corrected by providing hydrocortisone and fludrocortisone, respectively. It may be necessary to add sodium chloride to infant feeds. Treatment is lifelong. If compliance is poor, excess androgen production, accelerated growth, secondary central precocious puberty and, in boys, adrenal rest tumours can occur, as in the following case.

A boy was diagnosed with classic salt-losing CAH at 3 weeks of age. He was well controlled until his 8th birthday, but his compliance then became erratic. Onset of puberty was at 10 years 9 months and development was complete 4 years later. He was then craving salty food and had orthostatic hypotension. Testicular size was normal, but the consistency on the left was unusually firm. The plasma 17-OHP and immunoreactive renin levels were elevated. On ultrasound the testes showed well-defined, bilateral, oval hypo-echoic masses (Fig. 1) compatible with adrenal rest tumours. The patient was counselled regarding the importance of compliance and dexamethosone and fludrocortisone dosages were carefully monitored. Within 10 months he was asymptomatic, with no orthostatic hypotension. Both testicles were soft, biochemical

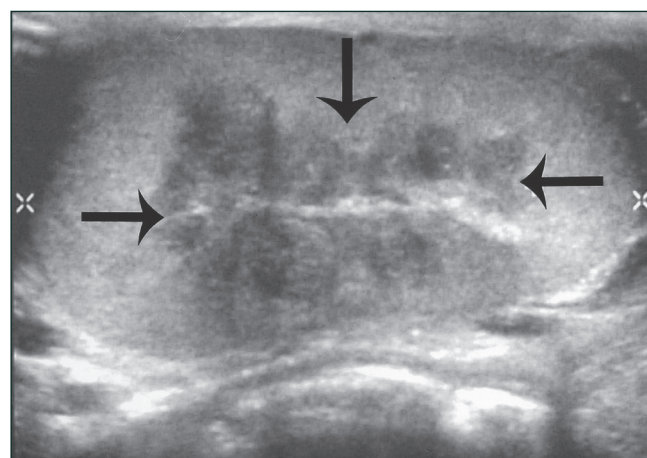


Fig. 1. Longitudinal scan through the testis (cursors), showing well-defined, hypo-echoic mass (arrows) compatible with an adrenal rest tumour.

parameters were normal and on ultrasound the adrenal rest tumours had shrunk.

Adrenal rest tumours are thought to originate from aberrant adrenal cells which migrate along with the descending testes, becoming hyperplastic when stimulated by adrenocorticotropin (ACTH).² While rarely clinically recognisable as palpable nodules, they are commonly detected on ultrasound examination in young males with CAH.³ They can compromise endocrine testicular function and spermatogenesis with decreased testosterone production and impaired semen quality.³ They usually regress when steroid therapy is increased to suppress ACTH. With adequate treatment fertility may be possible,⁴ but some tumours are steroid-unresponsive and require enucleation.

It has therefore been proposed that ultrasound examination, which is non-invasive, cost-effective, easy to perform and readily available, is offered to every pubescent or young adult male with CAH.³ Early detection and adequate treatment limit further complications and improve quality of life.

Ekkehard Zöllner was previously a paediatric endocrinologist at Red Cross War Memorial Children's Hospital, Groote Schuur Hospital and the School of Child and Adolescent Health, University of Cape Town. He is currently Head of the Paediatric Endocrine Unit at Tygerberg Hospital and Stellenbosch University.

Richard Pitcher is Head of the Division of Paediatric Radiology at Red Cross War Memorial Children's Hospital and the University of Cape Town.

Corresponding author: R Pitcher (pitcher@iafrica.com)

1. Huma Z, Crawford C, New MI. Congenital adrenal hyperplasia. In: Brook GD, ed. *Clinical Paediatric Endocrinology*. Oxford: Blackwell Science, 1995: 536-557.
2. Stikkelbroeck NM, Suliman HM, Otten BJ, Hermus ARMM, Blickman JG, Jager GJ. Testicular adrenal rest tumours in postpubertal males with congenital adrenal hyperplasia: sonographic and MR features. *Eur Radiol* 2003; 13: 1597-1603.
3. Stikkelbroeck NM, Otten BJ, Pasic A, et al. High prevalence of testicular adrenal rest tumors, impaired spermatogenesis, and Leydig cell failure in adolescent and adult males with congenital adrenal hyperplasia. *J Clin Endocrinol Metab* 2001; 86: 5721-5728.
4. Cunnah D, Perry L, Dacie JA, et al. Bilateral testicular tumours in congenital adrenal hyperplasia: a continuing diagnostic and therapeutic dilemma. *Clin Endocrinol (Oxf)* 1989; 30(2): 141-147.